JOURNAL OF CURRENT TRENDS IN CLINICAL MEDICINE & LABORATORY BIOCHEMISTRY

CASE REPORT

Fused Typical Cervical Vertebra – A Case Report

[1]N.Anandaramajayan*, [2]K.C.Mallikarjuna.

ABSTRACT

Typical cervical vertebra is 4 in number and they are C3, C4, C5&C6. They have similar characteristic feature by having small oval body, triangular vertebral foramen, bifid spinous process, superior and inferior articular process, transverse process & foramen transversarium for the passage of vertebral artery. This cervical vertebra may be fused by birth or acquired by diseases. This fused cervical vertebra may lead to many clinical significant like Klipel- Feil syndrome, so the case is studied .

KEY WORDS : Cervical Vertebra, Zygapophyseal joint, Conginatal, Body

Introduction

Cervical vertebra is the smallest vertebrae, characterized by the presence small oval body, triangular vertebral foramen, bifid spinous process, superior and inferior articular process, transverse process & foramen transversarium. It is classified into typical & atypical vertebra. Typical vertebras are c3 to c6 and atypical vertebra is c1, c2 & c7. When this vertebra fuses with one another it leads to block vertebra [1]. Sacrum is one of the best examples of block vertebra.

[1]Tutor, [2] Professor and Head,
Department of Anatomy,
Sri Lakshmi Narayana Institute of Medical Sciences,
Osudu, Puducherry.

***Corresponding Author**
N.Anandaramajayan,
Tutor of Anatomy,
Sri Lakshmi Narayana Institute of Medical Sciences,
Puducherry- 605 502, India.
E-Mail: anandaraman2006@gmail.com

They are also seen in lumbar region and thoracic region [2]. Fusion of vertebra may be due to congenital or acquired. Congenital fusion may be due to embryological reasons & Acquired due to diseases like Juvenile rheumatoid arthritis, Trauma & TB. Anomalies of the lower cervical vertebra lead to Klipel-Feil syndrome [3].

Observation

During the routine osteology demonstration class for 1st M.B.B.S students in the department of Anatomy at Sri Lakshmi Narayana institute of medical sciences, Puducherry, we found a fused typical cervical vertebra, the following things were observed in the vertebra:

1. Posterior aspect of the body was fused (Fig.No-3).
2. Anterior aspect of the body was not fused (Fig.No-1).
3. Both the zygapophyseal joints were fused with one another (Fig.No-2).

4. Lamina of the vertebra on the right side was completely fused with one another& on the left side it was not completely fused (fig.No-2).
5. Spinous process of the above and below vertebra was fused till the bifid of the spinous process.
6. The lateral aspect of the body of cervical vertebra was raised and there was a cleft on both the lateral border (Fig.No-4).
7. The superior articulating process of the vertebra was concave.

Discussion

Embryological cervical vertebra develops from the somite, which forms the sclerotome and surrounds the notochord. The caudal half of each sclerotome joins with the cranial half of the sclerotome to form a single vertebra. Failure of segmentation of the caudal and cranial sclerotome leads to block vertebra [4]. This may be due to decrease in blood supply during the 3rd - 8th week of fetal development. Fused cervical vertebra are similar in both structural and functional aspect[3]. Fusion is mainly seen in male as 5:1 as high incident of 0.75-3%[5]. A short neck, Low hair line and restricted neck motion or found in more than 2/3rd of cases. In fused cervical vertebra the anteroposterior diameter are similar to that of an unfused vertebra including the intervertebral disc. Congenitally fused vertebrae results in biochemical stress in the adjoining segment of the vertebral column leading to degenerative changes leading to distal tear, spondylosis[6-7]. Fused cervical vertebra also leads to clinical signs and symptoms like shortening of spine in cervical region, trapezei may be unduly prominent laterally, webbing of the neck, limited neck movement, lowered hair line, osseous malformations, scoliosis, kyphosis & torticollis leading to peripheral nerve irriation such as pain, burning sensation and cramp which are the signs of klippel-feil syndrome[3,8]. Symptoms are developed after the second decade of life mainly due to ligamentous laxity and aging, leading to sudden quadriplegia or death of the patients, initiated with minor trauma, such as tripping or falling out of bed [9]. Early diagnosis of the syndrome using CT or MRI will help the patients to change the life style and also gives a chance to live a normal life [10].

Conclusion

Knowledge of fusion cranio-verteberal anomalies is essential for clinical radiologists, anesthesiologist, orthopedic and neurosurgeons.

Fig.No-1 Showing the anterior view of fused cervical vertebra (unfused in the anterior aspect)

Fig.No-2: Showing the posterior view of fused cervical vertebra (completely fused in the posterior aspect)

Fig.No-3: Showing the posterior aspect of the body of the cervical vertebra fuses with one another

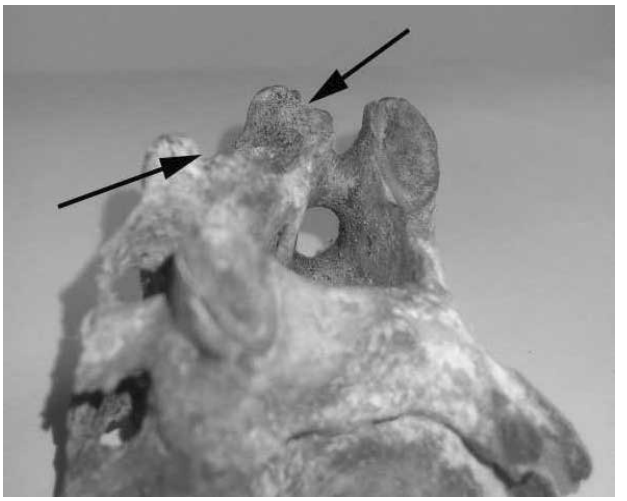

Fig.No.-4: Showing a cleft on either side of the body of the vertebra (arrow mark)

References:

1. Henry grays. Gray's Anatomy.39TH ed. Susan Standring, editor. Elsevier Churchill Livingstone; 2005.743-746 p.
2. Veena Vidya Shankar, Roopa R Kulkarni. Block vertebra: fusion of axis with the third cervical vertebra – a case report. Int J Anat Var. 2011; 4:15–8.
3. Imran S S 1, Dinanath Pujari 2, Uzair S H 3. Congenitally Fused Cervical Vertebrae. Anat Karnataka. 2012; Vol-6(3):73–5.
4. Radhika Paramesh Mudaliar1, Shailaja Shetty2, Komala Nanjundaiah3, Prathap Kumar J4,, Jyothi KC5. An Osteological Study of Occipitocervical Synostosis: Its Embryological and Clinical Significance. J Clin Diagn Res. 2013; 7(9):1835–7.
5. Aysegul ALTUNKAS, Basar SARIKAYA. Multiple congenital vertebral anomalies identified with multidetector CT. Int J Anat Var. 2009; 2: 2–3.
6. Singh Ajitpal Sekhon, Jeewanjot. Congenital Fused Cervical Vertebrae – A Case report. Int Ann Adv Sci Res. 2014; 1(3):026–31.
7. Erdil, H;, Yildiz, N;, Cimen, M. Congenital Fusion Of Cervical Vertebrae and Its Clinical Significance. J Anat Soc India. 2003; 52(2):125–7.
8. , A., Chandra, N., Naresh, M., Pandey, A.,, Tiwari, K. Congenital Abnormal Cervical Vertebrae–A Case Report. J Anat Soc India. 2002;51(1):68–9.
9. Hideki Nagashima, yasuo Morio, Ryota Teshima. No neurological involvement for more than 40 years in klippel-Feil syndrome with severs hypermobility of the upper cervicaql spine. Arch Orthop Trauma Surg. 2001; 121: 99–101.
10. Yogesh Yadav, Preeti Goswami,, Veena Bharihoke. Cervical Vertebra Synostosis (C2-C3) - A Case Report. Am J Med Case Rep. 2014; 2(6):120–2.